

A 6-Year-Old With Leg Cramps

Brian P. Jenssen, MD^{a,b}, Andrew J. Lautz, MD^c, Jennifer L. Orthmann-Murphy, MD, PhD^a, Sabrina W. Yum, MD^a, Angela Waanders, MD^a, Elizabeth Fox, MD^a

abstract

A 6-year-old girl presented with a history of leg pain and cramping that progressively worsened over a 2- to 3-week period of time. Her examination was notable for normal vital signs, limited range of motion of her left hip, and a limp. Inflammatory markers were slightly elevated, but the serum electrolytes, calcium, and magnesium, complete blood cell count and differential, and creatine kinase level were normal. She was hospitalized for further diagnostic evaluation and was noted to have abnormal muscle movements classified as myokymia (continuous involuntary quivering, rippling, or undulating movement of muscles). Electromyography confirmed the myokymia but did not reveal evidence of a myopathy or neuropathy, prompting additional evaluation for a systemic etiology.



Departments of ^aPediatrics, and ^bAnesthesiology and Critical Care Medicine, The Children's Hospital of Philadelphia, Philadelphia, Pennsylvania; and ^cUniversity of Pennsylvania, Robert Wood Johnson Foundation Clinical Scholar Program, Philadelphia, Pennsylvania

Dr Jenssen contributed to the conception and design of this case presentation, drafted the initial manuscript, and revised the manuscript; Drs Lautz, Orthmann-Murphy, Yum, Waanders, and Fox contributed to the conception and design of this case presentation and reviewed and revised the manuscript; and all authors approved the final manuscript as submitted.

www.pediatrics.org/cgi/doi/10.1542/peds.2015-0332

DOI: 10.1542/peds.2015-0332

Accepted for publication Apr 24, 2015

Address correspondence to Brian P. Jenssen, MD, 1310 Blockley Hall, 423 Guardian Dr, Philadelphia, PA 19104. E-mail: jenssenb@email.chop.edu

PEDIATRICS (ISSN Numbers: Print, 0031-4005; Online, 1098-4275).

Copyright © 2015 by the American Academy of Pediatrics

FINANCIAL DISCLOSURE: The authors have indicated they have no financial relationships relevant to this article to disclose.

FUNDING: No external funding.

POTENTIAL CONFLICT OF INTEREST: The authors have indicated they have no potential conflicts of interest to disclose.

DR BRIAN JENSSEN (PEDIATRICS, CHIEF RESIDENT)

A 6-year-old girl presented to her primary care physician with a complaint of severe leg cramping. The cramping was localized to her right thigh, leg, and toes, occurred while she was at school during gym class, and stopped after resting. She had 1 similar episode 1 week before presentation. The patient was generally very active, participating in dance classes and swimming regularly. She had no pain with ambulation, no fever, and was otherwise well. She was reported to have a normal physical examination, with no limited range of motion of her joints or other pertinent findings on her musculoskeletal examination. Dr Rezet, is this presentation consistent with growing pains?

DR BETH REZET (PEDIATRIC PRIMARY CARE)

The term *growing pains* is a bit of a misnomer. Growing pains often have nothing to do with growing and are not seen during periods of rapid growth. Some experts pushed to

rename this phenomenon “noninflammatory pain of early childhood,” but the term *growing pains* has persisted. They occur most often in children aged 4 to 6 years and in girls more than boys, but they are a diagnosis of exclusion. Usually the symptoms are bilateral, occurring in the muscles of the upper anterior thigh and calves, but they do not tend to involve toes and certainly do not involve joints. There should not be any point tenderness. The quality of pain is often aching. Temporally, they do occur in the midafternoon, in the evening, and especially at night. They are not associated with fever or change in gait. With growing pains, massaging the area typically improves the pain. With more concerning diagnoses, pain is often increased if one tries to massage the affected area. Overall, there are some aspects of this patient’s presentation that support a diagnosis of growing pains, but the “crampy” quality and unilateral nature decrease the likelihood of this diagnosis. Additionally, growing pains is a diagnosis of exclusion; often, a physician has to watch and wait.¹

DR JOE ST GEME (CHAIR, DEPARTMENT OF PEDIATRICS)

Dr Rezet, would you watch and wait at this point or pursue a diagnostic evaluation?

DR REZET

I probably would watch and wait, though I would be suspicious of saying that the diagnosis is growing pains, as opposed to a minor injury. The patient is very active, and I would want to see her back in the office for follow-up, especially if there are any new complaints.

DR JENSSEN

The patient received a diagnosis of potential growing pains, but her pediatrician emphasized the need for close follow-up if the symptoms persisted. The symptoms did persist, increasing in frequency, duration, and severity, and the patient was referred to our emergency department at the Children's Hospital of Philadelphia. Additional questioning revealed that the patient's symptoms were worsening over the past 2 weeks, with cramps, pain, and intermittent spasms, lasting ~15 minutes and occurring every half hour. The patient's mother described visible spasms in her daughter's right leg. Additional symptoms included a stabbing quality to the pain that was severe enough to prevent the patient from playing, causing her to walk with a limp using her left leg more than her right leg and resulting in visible spasms during sleep.

The family denied fever, recent upper respiratory symptoms, rash, weight loss, fatigue, altered mood, joint swelling, or recent trauma. There was no history of weakness in the upper extremities, no change in bowel or bladder function, and no difficulty breathing or other respiratory complaints. There was no family history of rheumatologic or autoimmune disease. The patient's 2-and-a-half-year-old brother had

a likely septic arthritis of the knee at 10 months of age, which was treated and resolved. The patient lives at home with her mother, father, and brother, all of whom are well. She attends school and is involved in acrobatics, swimming, and ballet. She takes no medications, and her immunizations are up to date.

Dr Osterhoudt, given this patient's history, what are your primary diagnostic considerations?

DR KEVIN OSTERHOUDT (PEDIATRIC EMERGENCY MEDICINE)

Cramping is an interesting chief complaint. Nighttime cramps are very common, and probably two-thirds of the people in this room will get them periodically. So infrequent cramps, resulting in waking from sleep, are not atypical. Cramps occurring at an accelerating frequency, now up to every half hour, are unusual, especially among this age group. The most common cause of cramping is exertion and overexertion.² This patient is a swimmer and a gymnast, but I do not think this patient was ever overexerting herself to the point that she would have that degree of cramping. Other considerations are hypocalcemia and hypomagnesemia, which would be higher on the differential if she had a particularly abnormal diet. Less frequently, one can see cramping-like symptoms from neuropathies or radiculopathies in the resolving picture of Guillain-Barré syndrome, muscle disorders (such as muscular dystrophies, inflammatory myopathy, metabolic myopathies, or myotonic syndromes), or occasionally associated with Lyme disease. Thyroid dysfunction should also be in the differential diagnosis of muscle cramp.

DR JENSSEN

On examination in the emergency department, the patient was noted to have a temperature of 36.8°C, a heart rate of 97 beats per minute, a respiratory rate of 22 breaths per

minute, a blood pressure of 94/55 mm Hg, and an oxygen saturation of 100% on room air by pulse oximetry. She was at the 50th percentile for weight and the 75th percentile for height for her age. In general, she was alert, well developed, well nourished, and in no acute distress. She had no cardiac murmur, her pulses were symmetric, and her capillary refill was normal. Her lungs were clear, and her abdomen was soft, nontender, and nondistended, without palpable organomegaly or palpable mass. On musculoskeletal examination, she had decreased internal and external rotation of her left hip, with normal range of motion of her right hip and weakness of her left hip flexors; there was no limited range of motion in her upper extremities. On neurologic examination, she had normal mentation and speech. Cranial nerve examination, including her extraocular movement and facial strength, was normal. There was no nystagmus or other abnormal eye movements. She had normal muscle tone, bulk, and strength in arms and legs. Sensation was normal. Deep tendon reflexes were normal and symmetric in arms, slightly brisk at the knees, and difficult to obtain at the ankles, with downgoing toes. She was able to ambulate independently but had an abnormal gait; she had decreased weight bearing on her left leg.

Dr Weiss, could this be arthritis, myositis, or a diagnosis such as dermatomyositis?

DR PAMELA WEISS (PEDIATRIC RHEUMATOLOGY)

Dermatomyositis often involves the hip flexors, but other proximal muscle groups including those around the shoulder, abdomen, neck, and thighs can also be involved. Unilateral presentation would not be consistent with dermatomyositis. The leg and toe pain that the patient presented with would be atypical for dermatomyositis as well, unless she had some referred pain or altered gait

or mechanics leading to secondary distal muscle involvement. One can see arthritis with dermatomyositis, and hip involvement could be consistent with this diagnosis, but the unilateral nature of the symptoms is atypical. Although they are not always present, she also does not have any cutaneous symptoms, such as Gottron papules, a heliotrope rash on the upper eyelids, malar rash on the face, photosensitivity, or vasculitic lesions, also decreasing the likelihood of this diagnosis.

DR JENSSEN

What would be helpful diagnostically?

DR WEISS

Muscle enzymes would be very helpful and include creatine kinase (CK), lactate dehydrogenase, aspartate aminotransferase, and aldolase. CK would be the first to rise and first to fall, and aldolase would be the last to rise and fall.³ Inflammatory markers, specifically erythrocyte sedimentation rate (ESR) and C-reactive protein, would also be helpful. For myositis, inflammatory markers would be normal or slightly elevated. If inflammatory markers were elevated and rhabdomyolysis was a concern, a urinalysis, with urine dipstick, examining for myoglobinuria could be of use. Viral studies could be helpful, because several viruses, including influenza B, can cause myositis. Additionally, from an imaging standpoint, an ultrasound of the hip would be noninvasive and would help identify any hip pathology, including arthritis.

DR JENSSEN

The serum levels of sodium, potassium, chloride, bicarbonate, total calcium, and magnesium and the complete blood cell count and differential were normal. Inflammatory markers were slightly elevated (ESR 50 mm/hour, C-reactive protein 1.8 mg/L), and

serum CK was 187 IU/L (normal; reference range 75–230 IU/L). Selected laboratory test results are detailed in Table 1. Plain radiographs of the hips and pelvis showed no bony abnormalities. An ultrasound of the hips was normal, with symmetric appearance and no fluid accumulation.

Because the pain and cramping were so debilitating that the patient was unable to function, and because of the diagnostic uncertainty, she was admitted to the general pediatrics service for additional evaluation. Dr Bonafide, if this patient were admitted to your service, how would you approach this case? What additional specialists, if any, would you call on for guidance?

DR CHRIS BONAFIDE (GENERAL PEDIATRICS HOSPITALIST)

I am impressed by the course of her illness, in that it is clearly progressive and worsening, occurring initially

intermittently and infrequently but now occurring almost continuously. The progressive nature and the intensity seem to argue against growing pains. Could this be a potential conversion disorder after a recent injury? Or could this be something more serious, potentially even life-threatening? From an electrolyte abnormality standpoint, we know that her potassium, calcium, and magnesium are normal. With a normal CK, I think the major myopathies are less likely. Could this be a potential peripheral manifestation of an underlying central nervous system abnormality, and should we be concerned about a potential seizure disorder or spinal cord process? The patient has normal bowel and bladder function and appears to have normal sensation and strength in her lower extremities, so spinal cord pathology is less likely. Could this be a peripheral nerve abnormality, such as Guillain-Barré syndrome, or a neuromuscular

TABLE 1 Laboratory Data

Test	Reference Range	Emergency Department Laboratory Value
Sodium, mmol/L	138–145	137
Potassium, mmol/L	4.1–5.8	4.4
Chloride, mmol/L	98–106	99
Carbon dioxide, mmol/L	20–26	24
Urea nitrogen, mg/dL	2–19	13
Creatinine, mg/dL	0.1–0.4	0.4
Glucose, mg/dL	74–127	92
Calcium, mg/dL	8.7–9.8	9.9
Magnesium, mg/dL	1.5–2.3	2.1
Total bilirubin, mg/dL	0.6–1.4	0.9
Total protein, g/dL	5.4–7.0	5.7
Albumin, g/dL	3.5–4.6	4.0
Alkaline phosphatase, U/L	145–320	160
Alanine aminotransferase, U/L	5–45	35
Aspartate aminotransferase, U/L	20–60	40
White blood cell count, thousand cells/ μ L	4.86–13.18	5.9
Differential, %		
Immature granulocytes	0.0–0.8	0.5
Segmented neutrophils	22.4–69.0	66.0
Lymphocytes	18.1–68.6	24.0
Monocytes	4.1–11.4	9
Eosinophils	0.0–3.3	0.5
Nucleated red blood cell count, per 100 white blood cells	0.0–0.0	0.0
Hemoglobin, g/dL	11.5–13.5	11.5
Platelet count, thousand cells/ μ L	189–394	194
Thyroid-stimulating hormone, μ IU/L	0.5–4.5	4.0
Thyroxine, free, ng/dL	0.7–2.00	1.4

junction abnormality, such as myasthenia gravis? Her symptoms and course do not appear to fit either of those diagnoses. Finally, I would be concerned about systemic problems that may present in this manner, such as an underlying channelopathy, endocrinopathies such as hyperthyroidism or hypothyroidism, or potential toxic exposures.

DR JENSSEN

Dr Weiss, regarding Dr Bonafide's point about a normal CK decreasing the likelihood of common myopathies, are there additional laboratory values that you would obtain at this point?

DR WEISS

Yes, I would check the previously mentioned muscle enzymes. We have seen dermatomyositis in patients who have a normal CK, so a normal CK does not completely rule out the diagnosis.³ Additionally, a red flag from a rheumatologic perspective is calf pain. Whenever we hear about calf pain, we worry about certain diagnoses, such as polyarteritis nodosum (PAN), which can be associated with neuropathic signs. For this patient, however, her ESR is only moderately elevated at 50 mm/hour, and classically the majority of patients with PAN have very high ESR levels, often >100 mm/hour. Additionally, patients with PAN are usually not well appearing at presentation.

DR JENSSEN

On the first night after admission into the next morning, the team noticed that the patient had particular, abnormal muscle movements (Supplemental Video). Dr Yum, what do we see on this video? Are these abnormal muscle movements fasciculations?

DR SABRINA YUM (PEDIATRIC NEUROLOGY)

No, these are not fasciculations, which manifest as brief twitching of muscle fibers of an individual motor unit that usually does not cause movement of the whole muscles or joints. What you see in the video is continuous involuntary quivering and undulating movements spreading across her calf muscles, characteristic of myokymia. You can think of myokymia as continuous "group fasciculations" in that it involves muscle fibers of >1 motor unit and is caused by spontaneous repetitive discharges from the same group of motor units. The numbers of motor units involved varies widely and may change from burst to burst. Therefore, the appearance of the muscle movement may change from time to time. I should also point out that whenever involuntary muscle contraction is seen, the first step is to distinguish neuromuscular involuntary muscle contraction from involuntary movement disorders of the central nervous system (eg, chorea, myoclonic jerks, athetoid movement, or dystonia); she did not have any signs of a movement disorder on examination. With regard to myokymic discharges, the origin probably involves spontaneous depolarization along a demyelinated segment of nerve and is a sign of nerve hyperexcitability. Myokymia may be segmental or may be diffuse. A toxic exposure or processes that cause nerve denervation can cause myokymia, leading to a broad differential diagnosis,⁴ although it is commonly associated with radiation injury of nerves (especially the brachial plexus), hypocalcemia, or a manifestation of neuromyotonia frequently associated with an autoimmune-mediated nerve potassium channelopathy.⁵ When it is found on the face, one should consider a pontine tumor or multiple sclerosis. It is occasionally seen in radiculopathy, entrapment neuropathy, Guillain-Barré syndrome,

or chronic inflammatory demyelinating neuropathy. It can also be seen in genetic conditions such as episodic ataxia with myokymia due to mutations of the *KCNA1* gene resulting in alternation of the voltage-gated potassium channels. Giving the list of the differential diagnosis, I would recommend starting the workup with a nerve conduction and electromyography (EMG) to confirm the diagnosis of myokymia and to look for other signs of nerve hyperexcitability, and to evaluate for a neurogenic process. I would also recommend performing MRI of the thoracic and lumbar spinal cord, without and with contrast, given that the myokymia was seen only in her legs.

DR JENSSEN

An EEG was normal, despite the abnormal muscle movements during the test. An electrocardiogram was performed because of concern for a potential channelopathy, revealing Δ waves, and a short PR interval of 60 ms, consistent with a diagnosis of Wolff-Parkinson-White (WPW) syndrome. Dr Nandi, could this diagnosis be associated with what seems like a potential underlying myopathy in our patient?

DR DEIP NANDI (PEDIATRIC CARDIOLOGY)

We do not often think of cardiac channelopathies presenting with muscle findings. There is 1 classic disease, Danon disease, where glycogen accumulates in heart tissue, resulting in development of massive cardiac hypertrophy, often with WPW syndrome as well. There are case reports of WPW syndrome in Duchenne or Becker muscular dystrophies, but those findings are really coincidental as opposed to casually related. I think this is an incidental finding, unrelated to this patient's underlying diagnosis.

DR JENSSEN

An MRI of the patient's lumbar and thoracic spine, with and without contrast, revealed no spinal pathology. The nerve conduction study did not show a neuropathy. Needle EMG showed myokymic discharges in many leg muscles, especially in the calves and thigh muscles, as well as neuromyotonic discharge in the biceps. There were no myopathic or neuropathic changes, or continuous firing of motor units. Dr Yum, what is neuromyotonia?

DR YUM

Neuromyotonia, like myotonia, manifests as delayed muscle relaxation, such as difficulty releasing hand grip. If you were to percuss a patient's muscle with a reflex hammer, you would see an indentation of the muscle that would then take several seconds to return to baseline. With percussion of the thenar muscles or wrist extensors, you would see prolonged abduction of the thumb or "hang up of the hand," respectively. Neuromyotonia is different from myotonia in that the former is thought to result from damaged peripheral axons, whereas the latter has muscle origin that is often seen in myotonic syndromes such as myotonic dystrophy, myotonia congenita, paramyotonia, or periodic paralysis. Neuromyotonia can be difficult to distinguish from myotonia clinically. However, neuromyotonic discharges of nerve origin can be easily differentiated from myotonic discharges of muscle origin on EMG. Neuromyotonic discharges are high frequency (15–250 Hz), decrementing, repetitive discharges of a single motor unit and are often seen along with fasciculations and myokymic discharges; all of them are considered abnormal spontaneous activity of nerve origin. During EMG, 3 components are assessed: abnormal spontaneous activity (when the muscle examined is relaxed), motor

unit potential morphology, and recruitment pattern (when the muscle examined is activated by the patient). Abnormal spontaneous activities can result from abnormal motor unit potentials of nerve origin, as mentioned above, or from abnormal muscle fiber potentials (as in fibrillations and positive sharp waves derived from extracellular recording of a single muscle fiber, or myotonic discharges derived from a single muscle fiber, with waxing and waning in amplitude and frequency). Because of the delayed relaxation of muscles, patients with neuromyotonia often have muscle stiffness, which I imagine this patient has. To sum it up, this patient has neuromyotonia based on her clinical features and EMG findings, a disorder of generalized peripheral nerve hyperexcitability. I should also point out that neuromyotonia has been described variously as Isaac syndrome, pseudomyotonia, neurotonia, or normocalcemic tetany when it is acquired. In addition to muscle cramps, stiffness, and myokymia, some patients with neuromyotonia develop paresthesia, hyperhidrosis, confusion, mood change, and hallucination (Morvan syndrome).

DR ST GEME

Dr Yum, with these findings on EMG, do you think this is a diffuse process? The patient presented with focal complaints, but so far we have not found localized abnormalities on imaging studies.

DR YUM

With myokymic and neuromyotonic discharges but no signs of a neuropathy, neuronopathy, or myopathy on her nerve conduction and electromyographic examinations, yes, I would be concerned about a more systemic process, such as an autoimmune process or a paraneoplastic process.⁶ Therefore, imaging of the neck, chest, and

abdomen is indicated to look for neoplasm, and inflammatory markers and a paraneoplastic autoantibody panel should be sent.

DR JENSSEN

Thyroid studies, including thyroid-stimulating hormone and free T₄, were obtained and were normal. A lumbar puncture was performed, revealing 1 white blood cell and 2 red blood cells per cubic millimeter, glucose 10 mg/dL, and total protein 30 mg/dL in the cerebrospinal fluid (CSF). The CSF culture was sent and was negative. Known paraneoplastic antibodies from the CSF and serum were normal, including the voltage-gated potassium channel antibody. Additionally, anti-glutamic acid decarboxylase 65 antibody was negative.

With concern for a diffuse process such as a neoplasm causing the myokymia, computed tomography (CT) scan of the patient's chest, abdomen, and pelvis was performed, with and without both intravenous and oral contrast (Figs 1 and 2). Dr Fox, can you please comment on what is identified in these images?

DR ELIZABETH FOX (PEDIATRIC ONCOLOGY)

Figure 1 includes 2 coronal views and 1 axial view demonstrating 2 distinct masses. One is a well-circumscribed retroperitoneal mass (3 cm × 3.5 cm × 6 cm) with some central necrosis located adjacent to the aorta just below the left renal vein, and the other is a 5 × 3 × 6 cm paracolic mass, lateral to the left kidney. The masses are distinct and do not arise from the left adrenal gland or kidney.

This is a puzzling case. Paraneoplastic syndromes are rare in children. These masses do not appear invasive, and they could be nonmalignant. They could be something like an inflammatory myofibroblastic tumor or a neuroblastic tumor, such as a neuroblastoma, paraganglioma, or

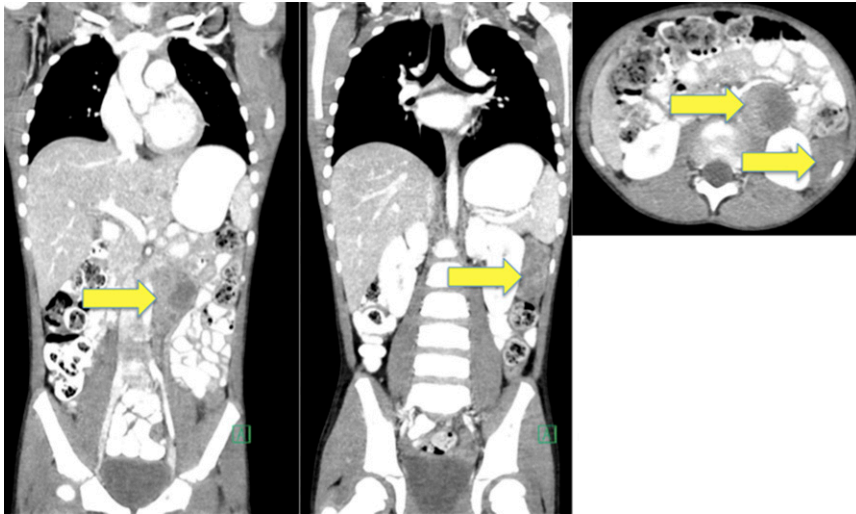


FIGURE 1
CT scan of the patient's chest, abdomen, and pelvis with and without both intravenous and oral contrast.

schwannoma. These masses could also be caused by a lymphoma, but that is less likely considering the clinical presentation and the laboratory findings to date. For additional evaluation of these masses, I would recommend a biopsy.

DR JENSSEN

A laparoscopic biopsy was performed, and a diagnosis of maturing

ganglioneuroma was made; however, the pathologist cautioned that because of potential sampling problems with a biopsy, a possible neuroblastic component could not be ruled out. While the team was discussing the need for additional diagnostic workup, additional laboratory results returned. The α -fetoprotein and human chorionic gonadotropin were normal; however, the urine vanillylmandelic acid to

homovanillic acid levels was elevated, at 5 to 10 times the upper limit of normal, increasing the probability of the presence of a secreting neuroendocrine tumor or neuroblastoma. With the concern for disseminated disease, a nuclear medicine meta-iodobenzylguanidine (MIBG) scan was performed (Fig 2). Dr Fox, what is this particular study, and what do we see on the images?

DR FOX

This is an iodinated MIBG nuclear medicine scan. MIBG is a molecule similar to noradrenaline that is taken up by cells expressing neuroepinephrine transporters. MIBG scans are specific because neuroepinephrine transporters are present on many neuroblastic tumors, and the normal tissue distribution of the transporter is restricted to the normal adrenal gland, salivary glands, and occasionally a small amount of diffuse uptake in the normal liver. In this case, the MIBG scan included single-photon emission computed tomography (SPECT), a low-dose CT scan fused with the nuclear medicine images to anatomically localize the MIBG-avid lesions. For our patient, the MIBG/SPECT identifies 2 masses. The retroperitoneal paraaortic mass is MIBG avid, but the lateral paracolic mass is not MIBG avid. In addition, the whole-body planar images demonstrate diffuse MIBG uptake in many of the patient's bones and bone marrow. She has normal uptake in salivary and adrenal glands and abnormal uptake in bone and bone marrow, MIBG uptake in the skull, sternum, and ribs, diffuse uptake throughout her entire spine, and uptake in bilateral shoulders, femurs, and proximal tibia.

DR JENSSEN

With the identified disseminated bony involvement and disease burden, the team decided that the appropriate course was full excision of the lesions for full histology, as well

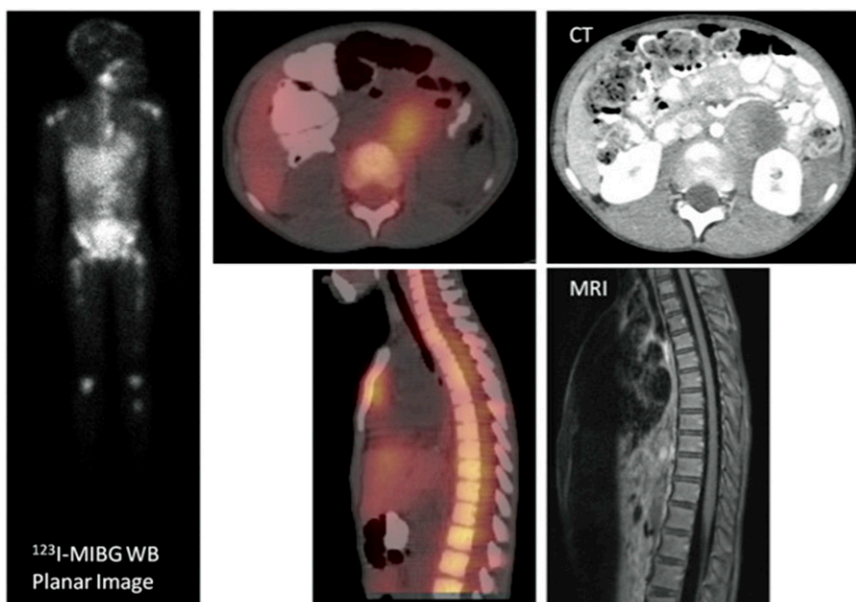


FIGURE 2
MIBG SPECT scan.

as bilateral bone marrow biopsies. Dr Dekio, can you comment on the pathology?

DR FUMIKO DEKIO (PATHOLOGY)

We received 2 specimens: a paracolic tumor and a retroperitoneal mass. The retroperitoneal mass was more concerning, with a large area of necrosis, small round blue cells, and neutrophils in the middle. The mass demonstrated 2 types of tumor cells: Neuroblastoma is the more immature, and the ganglioneuroma is the more mature.

FINAL DIAGNOSIS AND DISCUSSION

- Neuroblastoma, poorly differentiated, with bone marrow involvement
- Myokymia and generalized peripheral nerve hyperexcitability, probably secondary to a presumed paraneoplastic process

DR ANGELA WAANDERS (PEDIATRIC NEUROONCOLOGY)

This patient's presentation is not a typical paraneoplastic presentation of neuroblastoma. The more classic paraneoplastic presentation of neuroblastoma is opsoclonus myoclonus ataxia syndrome (OMAS). Opsoclonus is best described as chaotic random eye movements. Patients with nystagmus have an intersaccadic pause where their eyes are trying to focus; however, in patients with opsoclonus, there is no pause. Patients can first present with myoclonic jerks. The annual incidence is estimated at 0.2 to 2 per million children. (At the Children's Hospital of Philadelphia, we find 3–4 new cases per year.) Typical symptoms are cerebellum related. The typical age of onset is <5 years of age, there are usually no premorbid conditions, and affected patients usually have a rapid onset of neurologic decline. Additional symptoms include encephalopathy and behavior disturbances, impaired cognition with

regression of milestones, language dysfunction, hypotonia, and hyporeflexia.

The case highlights the multidisciplinary approach needed to coordinate an expedited cancer evaluation if a paraneoplastic syndrome is suspected. This can decrease delay in diagnosis and treatment. Approximately 2% to 3% of children with neuroblastoma have OMAS; conversely, ~50% of children with OMAS have neuroblastoma. Usually, with OMAS the neuroblastoma is low risk, with surgical resection often being the only tumor-directed treatment needed. Tumor-free progression and overall survival are often excellent. Unlike in other paraneoplastic syndromes, however, treating the tumor often does not improve the OMAS symptoms, with targeted treatment needed for the neurologic symptoms separately.

The underlying pathophysiology is not well understood. The hypothesis is a T-cell-dependent response to tumor-associated antigens leading to B-cell activation, but no biomarkers have been identified. Treatment focuses on immunotherapy, currently incorporating dexamethasone and rituximab. Additional questions for debate include the underlying cause of OMAS. Does an immune "assault" need to be present for one to develop OMAS, or does every patient with OMAS have neuroblastoma, with the undetected cases a product of spontaneous regression or limitations of current imaging modalities?

DR YUM

Symptomatic treatment of myokymia is a sodium channel blocker such as phenytoin, carbamazepine, or oxcarbazepine. Intravenous immunoglobulin or plasmapheresis might be helpful in the immune-mediated process, and symptoms may improve with surgical removal of the tumor. She was started on

oxcarbazepine (Trileptal), with great response over a several-week period of time. Our overall thought is that the underlying mechanism of neuromyotonia and myokymia in this patient is peripheral nerve hyperexcitability, probably secondary to a presumed antibody-mediated paraneoplastic process. We are currently working to identify the antibody and antigen in question.

DR FOX

The patient received a diagnosis of high-risk neuroblastoma, based on her age, the histology of her tumor, and the presence of extensive disease. Her prognosis is guarded: Children with high-risk neuroblastoma treated with surgery, intensive induction chemotherapy, radiation, and bone marrow transplant have a 2-year event-free survival of ~50%. The most recent advance in neuroblastoma therapy is immunotherapy administered after completion of multimodality therapy. Immunotherapy with anti-ganglioside G2 antibody (ch14.18) and cytokines (granulocyte macrophage colony-stimulating factor and interleukin-2) followed by administration of the differentiating agent isotretinoin has increased 2-year event-free survival to 65%.⁷ After diagnosis and initiation of chemotherapy, our patient was discharged from the hospital. Currently, she is doing well and has completed the second cycle of induction chemotherapy. Her myokymia improved on oxcarbazepine, then resolved. The oxcarbazepine has been discontinued without recurrence of myokymia.

ACKNOWLEDGMENTS

We thank Beth Rezet, MD, Kevin Osterhoudt, MD, Pamela Weiss, MD, Chris Bonafide, MD, Deip Nandi, MD, Fumiko Dekio, MD, and Joseph St Geme III, MD for sharing their time and expertise.

ABBREVIATIONS

CK: creatine kinase
CSF: cerebrospinal fluid
CT: computed tomography
EMG: electromyography
ESR: erythrocyte sedimentation rate
MIBG: meta-iodobenzylguanidine
OMAS: opsoclonus myoclonus ataxia syndrome
PAN: polyarteritis nodosum
SPECT: single-photon emission computed tomography
WPW: Wolff-Parkinson-White

REFERENCES

1. Weiser P. Approach to the patient with noninflammatory musculoskeletal pain. *Pediatr Clin North Am.* 2012;59(2): 471–492
2. Allen RE, Kirby KA. Nocturnal leg cramps. *Am Fam Physician.* 2012;86(4): 350–355
3. Breda L, Nozzi M, De Sanctis S, Chiarelli F. Laboratory tests in the diagnosis and follow-up of pediatric rheumatic diseases: an update. *Semin Arthritis Rheum.* 2010; 40(1):53–72
4. Piña-Garza JE. *Fenichel's Clinical Pediatric Neurology: A Signs and Symptoms Approach.* 7th ed. New York, NY: Elsevier Inc; 2013
5. Shillito P, Molenaar PC, Vincent A, et al. Acquired neuromyotonia: evidence for autoantibodies directed against K⁺ channels of peripheral nerves. *Ann Neurol.* 1995;38(5):714–722
6. Maddison P. Neuromyotonia. *Clin Neurophysiol.* 2006;117(10): 2118–2127
7. Yu AL, Gilman AL, Ozkaynak MF, et al; Children's Oncology Group. Anti-GD2 antibody with GM-CSF, interleukin-2, and isotretinoin for neuroblastoma. *N Engl J Med.* 2010;363(14):1324–1334

HEARTS OF PALM: *While I like many salads and salad ingredients, one of my favorite additions to a summer salad are hearts of palm. I like the crunchiness, texture, and delicate flavor. As palm trees are not native to Vermont, I rarely see them served in area restaurants.*

As reported in Food and Wine (FWX: August 20, 2015), a heart of palm is a white vegetable harvested from the center or growing bud of certain palm trees. Large stems or the entire cultivated young palm tree is cut down to harvest the vegetable. First, the bark is removed from the stem, leaving concentric layers of white fibers around a pale center core. Next, the fibers are removed, leaving only the core or heart of palm. The vegetable resembles white asparagus in appearance. Hearts of palm can be found fresh in some markets, but more often they are sold in cans or jars. Although it can be hard to tell how the hearts of palm were harvested, I prefer farmed over wild, because harvesting hearts of palm from wild or single stemmed trees often results in the death of the tree. Palm trees farmed for this vegetable have multiple and often up to 40 shoots, so harvesting several will not harm the plant. While generally served in salads, hearts of palm can be made into soups or dips. So, if you happen to have a child who does not like green vegetables, perhaps they might like the sweet taste of white hearts of palm.

Noted by WVR, MD

A 6-Year-Old With Leg Cramps

Brian P. Jenssen, Andrew J. Lautz, Jennifer L. Orthmann-Murphy, Sabrina W. Yum,
Angela Waanders and Elizabeth Fox

Pediatrics 2015;136;732

DOI: 10.1542/peds.2015-0332 originally published online September 14, 2015;

Updated Information & Services	including high resolution figures, can be found at: http://pediatrics.aappublications.org/content/136/4/732
References	This article cites 6 articles, 0 of which you can access for free at: http://pediatrics.aappublications.org/content/136/4/732#BIBL
Subspecialty Collections	This article, along with others on similar topics, appears in the following collection(s): Medical Education http://www.aappublications.org/cgi/collection/medical_education_sub
Permissions & Licensing	Information about reproducing this article in parts (figures, tables) or in its entirety can be found online at: http://www.aappublications.org/site/misc/Permissions.xhtml
Reprints	Information about ordering reprints can be found online: http://www.aappublications.org/site/misc/reprints.xhtml

American Academy of Pediatrics

DEDICATED TO THE HEALTH OF ALL CHILDREN™



PEDIATRICS®

OFFICIAL JOURNAL OF THE AMERICAN ACADEMY OF PEDIATRICS

A 6-Year-Old With Leg Cramps

Brian P. Jenssen, Andrew J. Lutz, Jennifer L. Orthmann-Murphy, Sabrina W. Yum,
Angela Waanders and Elizabeth Fox

Pediatrics 2015;136;732

DOI: 10.1542/peds.2015-0332 originally published online September 14, 2015;

The online version of this article, along with updated information and services, is
located on the World Wide Web at:

<http://pediatrics.aappublications.org/content/136/4/732>

Data Supplement at:

<http://pediatrics.aappublications.org/content/suppl/2015/09/08/peds.2015-0332.DCSupplemental>

Pediatrics is the official journal of the American Academy of Pediatrics. A monthly publication, it has been published continuously since 1948. Pediatrics is owned, published, and trademarked by the American Academy of Pediatrics, 141 Northwest Point Boulevard, Elk Grove Village, Illinois, 60007. Copyright © 2015 by the American Academy of Pediatrics. All rights reserved. Print ISSN: 1073-0397.

American Academy of Pediatrics

DEDICATED TO THE HEALTH OF ALL CHILDREN™

